

See discussions, stats, and author profiles for this publication at: <https://www.researchgate.net/publication/5606198>

Progressive disc herniation: An investigation of the mechanism using radiologic, histochemical, and microscopic...

Article in *Spine* · January 2008

DOI: 10.1097/BRS.0b013e31815b64f5 · Source: PubMed

CITATIONS

51

READS

132

4 authors, including:



Janessa D M Drake

York University

31 PUBLICATIONS 393 CITATIONS

[SEE PROFILE](#)



Stuart M McGill

University of Waterloo

288 PUBLICATIONS 12,692 CITATIONS

[SEE PROFILE](#)

Some of the authors of this publication are also working on these related projects:



Interobserver and intraobserver variability in the calculation of lumbar intervertebral disc shape from MRI in health subjects [View project](#)

Progressive Disc Herniation

An Investigation of the Mechanism Using Radiologic, Histochemical, and Microscopic Dissection Techniques on a Porcine Model

Claudio Tampier, MD,*† Janessa D. M. Drake, MSc,† Jack P. Callaghan, PhD,†
and Stuart M. McGill, PhD†

Study Design. Basic scientific investigation using radiologic, histochemical, and microscopic dissection techniques.

Objective. To document the process of mechanically induced disc herniation from repetitive loading exposure.

Summary of Background Data. Current knowledge of the mechanism of disc herniation is limited to only a few postmortem studies with even fewer attempts to document the process of damage during the developing stages of herniation.

Methods. Sixteen porcine cervical spine motion segments (C3–C4) were mounted in a custom servo-hydraulic testing machine. The specimens were exposed to 1472 N of compressive load and cyclically flexed-extended in angular positional control to a minimum of 4400 cycles and a maximum of 14400 loading cycles. Measurements from radiologic, histochemical, and microscopic dissection techniques were used to document the progressive trauma.

Results. The experiment produced 8 complete herniations and 4 partial herniations, of which only 4 were diagnosed by contrast discogram. The progressive damage appears to develop with a small cleft (within layer spreading) inside the first inner layer of the annulus. The nuclear material was pressed through this cleft to create a fluid-filled, delaminated pocket between collagen fibers within a lamellar bundle in an annular layer. This was the first stage of damage and disc herniation production at a microscopic level. In full annular herniation, this process is repeated until the nucleus pulposus had tracked completely through the annulus.

Conclusion. The herniation process appears to proceed with nuclear material progressing through small clefts, which accumulates causing delamination within each lamella rather than between annulus layers. No rupture of annulus fibers was found. This knowledge will

assist in the development of prophylactic interventions. These data also suggest discordance between discographic indicators and other evidence confirming annular damage.

Key words: disc herniation, annulus, discogram, injury mechanism. **Spine 2007;32:2869–2874**

Disc herniation is one form of cumulative trauma in an adult intervertebral disc that is linked to time varying hydraulic responses. The process involves the passage of the nucleus pulposus through the annulus most typically in a posterior or posterior-lateral direction. Current knowledge of the mechanism behind the movement of the nucleus pulposus is not fully developed and is limited to only a few studies. Study of the herniation process is particularly challenging as it is difficult to detect initiation, and the stage of advancement of nucleus pulposus material through the annular layers. This investigation employed radiologic, histochemical, and microscopic dissection techniques to document and improve the understanding of the herniation process.

Several authors have proposed hypotheses for disc herniation. Adams and Hutton¹ produced gradual disc prolapse by applying compression loading and repetitive bending motion in cadaveric lumbar functional spine units (FSU). The authors monitored the gradual prolapse by direct observation and discogram and found the injury started with the lamellae of the annulus being distorted to form radial fissures.¹ The nuclear pulp was then extruded from the disc and sometimes into the spinal canal. Discs most commonly affected were from lower lumbar spinal levels of young cadavers,¹ suggesting that a nondegenerated, viscous nucleus may be influential. Gordon *et al*² applied a similar approach but used a more physiologically representative loading protocol, that being low level combined loading with highly repetitive compressive cycles, and produced annular protrusions and nuclear extrusion. Collectively, this work supports the hypothesis that intervertebral disc prolapse proceeds progressively from the inside outwards.

Although there is broad consensus of the importance of annular lesions among the macroscopic and microscopic features of intervertebral disc herniation, the origin and sequence of their development are less understood. Moore *et al*³ in a clinicopathologic study, examined disc tissue collected from surgery and from cadaveric spines. The authors concluded that nuclear

From *Asociación Chilena de Seguridad Valdivia and Instituto del Aparato Locomotor Universidad Austral de Chile, Chile; and †Spine Biomechanics Laboratory, Faculty of Applied Health Sciences, University of Waterloo, Waterloo, Ontario, Canada.

Acknowledgment date: October 17, 2007. Revision date: March 8, 2007. Acceptance date: April 18, 2007.

Supported by the Natural Science and Engineering Research Council of Canada (to S.M.M.) as well as the Asociación Chilena de Seguridad and the Universidad Austral de Chile (to C.T.), a Canadian Institute for the Relief of Pain and Disability/Canadian Institutes of Health Research Doctoral Research Award (to J.D.M.D.), and a Canada Research Chair in Spine Biomechanics and Injury Prevention (to J.P.C.). The manuscript submitted does not contain information about medical device(s)/drug(s).

Federal funds were received in support of this work. No benefits in any form have been or will be received from a commercial party related directly or indirectly to the subject of this manuscript.

Address correspondence and reprint requests to Stuart M. McGill, PhD, University of Waterloo, 200 University Avenue West, Waterloo, Ontario N1G 2G1, Canada; E-mail: mcgill@uwaterloo.ca

fragments migrate along preexisting radiating tears in the anulus.³ They reported that nuclear degeneration first becomes evident as a large cleft toward the periphery of the nucleus as it becomes less hydrated and shrinks, followed by nuclear clefting and fragmentation, which are well established as characteristics associated with the third decade of life.³ Moore *et al*³ found that the presence of isolated fragments of the anulus and the endplate are much less common within extruded material than the nucleus, and suggest these probably also originate as part of the degenerative processes. In contrast, Yasuma *et al*⁴ histologically examined intervertebral discs obtained at autopsy and material obtained from adult spine surgery. These researchers described how the bundle in the internal layer of the anulus fibrosus reversed their usual direction and showed myxomatous degeneration, sometimes resulting in posterior and convex bulging in the internal layer of the anterior and posterior parts of the anulus fibrosus, respectively.⁴ These results suggested that a protrusion type herniation, where only the anulus material is present, might be due to a reversal of bundles of the anulus fibrosus without the involvement of the nucleus pulposus. This type of herniation may involve different mechanisms than the type where nuclear material is protruded through a fissure in the anulus.

Finally, Lipson⁵ in a study based on experimental intervertebral degeneration, asserted that herniated disc material is actually newly synthesized proliferative metaplastic fibrocartilage and not preexisting disc tissue, particularly of nucleus origin. Surgically harvested tissues from intervertebral disc herniations were assessed with a hydroxypyridinium cross-link assay to determine the maturity of the collagen. His results suggested that the herniated disc material was a younger tissue than the *in situ* anulus fibrosus.⁵

Other researchers have hypothesized that herniation, at least during the repetitive flexion-extension exposure tested in this study, is a cumulative process of nucleus material tracking through the anulus.^{2,6} The objective of this research is to improve the understanding of the process and mechanism of mechanically induced herniation.

■ Materials and Methods

Disc Herniation Creation and Documentation Protocol

The cervical spines of 16 porcine (age mean 6 months, mass mean 80 kg) specimens (C1–T12) were obtained immediately following death. All specimens were sealed in doubled polyethylene bags and stored at -22°C . Before testing, the frozen specimens were thawed at 24°C for 14 hours. The surrounding musculature was stripped leaving the osteoligamentous structures intact. Sixteen FSUs were obtained from C3–C4 (2 adjacent vertebral bodies and the intervening intervertebral discs). The intervertebral discs of the sectioned ends of the specimens were examined for degeneration and were graded according to the scale proposed by Galante.⁷ All 16 specimens met the Grade 1 criteria and were accepted for the experiment. The Committee for Research on Humans, Office of Research Ethics, University of Waterloo approved this study.

The area of the exposed endplates (superior C3 and inferior C4) of the cervical porcine vertebrae was measured to evaluate resemblance in the size of the vertebral specimens as in the work of Callaghan and McGill.⁸ The endplate area was calculated using the equation for surface area of an ellipse ($\pi/4 * A * B$), where A is the anterior-posterior length and B is the medial-lateral width of the vertebral endplate. The average area of the 2 exposed endplates was used to represent the FSU area.

To assist in the documentation of progressive tracking of the nucleus pulposus leading to intervertebral disc herniation, a mixture of barium sulfate (radio-opaque), blue dye (Coomassie Brilliant Blue Gmix: 0.25% dye, 2.5% MeOH, 97.25% distilled water), and distilled water was mixed in a ratio of 2:1:2 and approximately 0.7 mL was injected into the intervertebral disc nucleus with a 23-gauge needle. The specimens were only injected with mixture material until there was resistance against the plunger of the syringe to prevent excessive pressure in the disc. This mixture has sufficient resistance to diffusion over the duration of the test so that movement of the barium sulfate only occurs with the movement of the nucleus pulposus.⁶ Specimens were fixed in aluminum cups using a nonexothermic dental stone (Denstone, Miles, South Bend, IN) and 16 gauge steel wire looped bilaterally around the anterior processes and the lamina of both vertebrae. One screw was used to hold each exposed endplate of the specimen in testing mounts. The screws pierced the center of the endplate at the mounted portion of the vertebra and never protruded farther than 10 mm into the vertebral body. The dental stone material only covered the proximal half of the cranial vertebra and the distal half of the caudal vertebra. Specimens were then radiographed to document the distribution of the nucleus in the sagittal and transverse planes.

The mounted specimens were then placed in a custom servo-hydraulic dynamic testing system (Model 8511, Instron Canada, Burlington, Ontario, Canada) that has been described previously.⁶ A preload (260 N for 15 minutes) was applied to all specimens to precondition the specimens and counter any swelling that had occurred postmortem. During this preloading phase, the servomotor was programmed to chase a zero flexion-extension moment magnitude and the angular position at the end of the preload was taken as zero position (achieving elastic equilibrium) for each specimen.

The specimens were then exposed to 1472 N of compressive load. The 1472 N compressive load represents approximately 14% to 22% of the average compressive strength of porcine cervical specimens reported in the literature.^{9–11} Previous work using the same test apparatus and specimen population has resulted in a documented compressive strength of 10.4 kN in a neutral posture.¹¹

In addition to the 1472 N compressive load, the specimens were cyclically loaded to 15° of flexion and to 2° of extension. These limits helped to preserve the disc tissue and avoided vertebral fracture, yet still produced herniations. The cyclic flexion-extension motions were produced in angular positional control at a rate of 1 Hz to a maximum of 14,400 cycles and minimum of 4400 cycles to capture various stages of the herniation process using a servomotor (Model BNR3018D, Cleveland Machine Controls, Billerica, MA) and a 40:1 planetary gear head (Model 34PL0400, Applied Motion Products, Watonsville, CA).

The specimens were radiographed following testing in an attempt to document disc herniations relative to sagittal and transverse plane structures. A second injection of a mixture of

barium sulfate and distilled water was administered to mimic rehydration that occurs naturally with daily cycles of real life. Pressure on the syringe was increased slowly until approximately 1 mL of the mixture was injected. A second discography was performed in order to assess if the additional injection increased the sensitivity of the radiograph for detecting herniation. A gross examination of the ligamentous structure and posterior elements was conducted and any failure or damage was recorded.

Histology and Microscopic Dissection Description

The neural arch of the specimens was removed at the base of the laminae with a saw and each vertebral body was cut in half transversely roughly through the middle of the vertebral body. The FSU was then further sectioned into right and left blocks. The histology study was performed on the disc from the right side of the FSU, and the left side was used for microscopic dissection. The sample of anulus fibrosus was cut in blocks of 5 mm height by 4 mm width with the length depending on the part of the disc (anterior or posterior). The sample was embedded in gelatin, enveloped by Tissue-Tek OCT compound (Optimum Cutting Temperature; Miles Laboratories, Elkhart, IN). The block of tissue embedded in gelatin was rapidly frozen to -150°C to -170°C by immersion in liquid nitrogen, so that it hardened to a solid mass owing to freezing of tissue water. The anterior and posterior parts of the disc were then sectioned transversely, sagittally, and in some cases at 45° of inclination. The thickness for each slice was set at $10\ \mu\text{m}$. The samples were cut on a special microtome housed in a refrigerated cabinet (a cryostat) (Thermo Electron Corp., Cheshire, UK). The sample was stained with hematoxylin and eosin to detect nucleus proteins for microscopy. A second light microscope (Hund, model Wilovert AFL 30) connected to a digital camera (Hitachi KPD 500) was used to analyze the samples in the slides and digitize the microscopic images.

The microscopic dissection was performed by an orthopedic surgeon (C.T.) with surgical instruments under a stereomicroscope (Nikon, SMZ1000, Japan) to document distribution of nuclear material in the anulus. The FSU was fixed with clamps and light traction, of approximately 10 N was applied with elastic bands along the axis of the spine, to facilitate the dissection and to standardize the shape of the anulus in the digital images. The different steps of dissection were registered with a digital camera (Nikon, Coolpix 5400) and the images were saved in Joint Photographic Experts Group (JPEG) format with a dimension of 2592×1944 pixels. A Nikon calibrated microscopic slide was used to obtain measurements of length.

Results

Disc Herniation Production

Interrupting the process of partial disc herniation for study rather than full and frank extrusion is challenging. Nonetheless, the experiment produced 8 complete herniations without extrusion (Figure 1), 4 partial herniations and 4 specimens without any microscopically detectable anular damage. In the 16 FSUs used, the average endplate area was $667.1 \pm 65.7\ \text{mm}^2$ and ranged from 587.1 to $799.1\ \text{mm}^2$. There were no statistical differences between the endplate area, number of cycles applied, and the occurrence of herniation ($P > 0.05$). In 2 FSUs, avulsion endplate fractures were produced in C4 after 7200 and 9000 cycles, respectively.

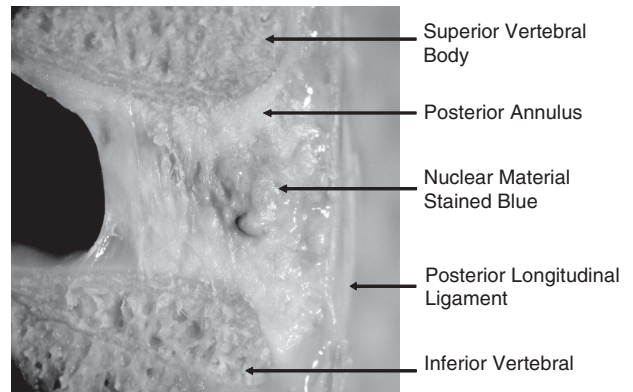


Figure 1. Complete disc herniations were defined when nucleus material tracked through the entire anulus but was contained by the posterior longitudinal ligament. The nucleus was stained with a blue dye to aid in identification.

Radiologic Evaluation

Fourteen of 16 FSUs were radiographed at the beginning and the end of the trial to evaluate the movement of the nucleus pulposus (2 cases were lost due to radiograph machine malfunction). Of the 8 specimens where the presence of complete disc herniation was defined by histochemical techniques, 4 disc herniations were diagnosed by radiographs and 3 were misdiagnosed. Of the 4 partial herniations, only 1 could be diagnosed using radiographic technique. There were no “false positive” observations.

Once the mechanical loading experiment was finished, a second discography was performed following the reinjection of additional radio-opaque contrast in an attempt to increase the sensitivity of the radiographic method. There was no change in diagnosis of disc herniation and the additional mixture of barium failed to improve the visibility or detectability of exact clefts/pathways where the nuclear material passed through the posterior anulus.

Microscopic Dissection Analysis

The microscopic dissection showed there was nuclear material reaching the posterior longitudinal ligament in 8 specimens; therefore, these specimens were classified as complete herniations. In 4 specimens, the nuclear mate-

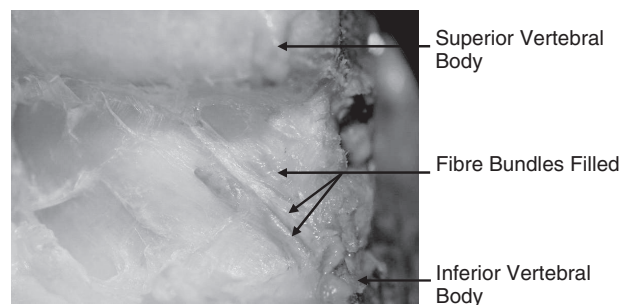


Figure 2. The nuclear material (stained blue) filled the fiber bundles within layers of the posterior annulus fibrosus lamellae, not between them. The tracks were parallel to the fibers within that particular lamella.

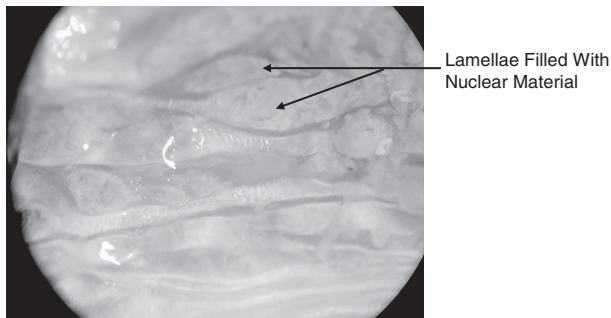


Figure 3. In a complete herniation, 2 adjacent lamellae were filled with nuclear material (stained purple). The lamellae walls were preserved and a pocket of the nuclear material was created.

rial was between the inner layer and the middle layer; consequently, these specimens were classified as partial herniations. There was no nuclear material found in the anterior anulus or between the lamellae layers. Nuclear material was found inside the lamella fiber bundles, and occupied volume inline with the orientation of the fibers (Figures 2, 3). In the posterior anulus fibrosus of 6 FSUs, a small cleft or path was found through the division between 2 adjacent lamella layers. Nuclear material was found communicating from 1 layer to the other through the cleft (Figures 4, 5). There was a spreading of adjacent fibers, and no rupture or failure of any of the anular fibers was detected.

Histologic Analysis

In 4 of the 16 specimens, there was no histologic evidence of tissue damage in the anterior and posterior anulus. In 4 other specimens, nuclear material was found inside the lamellae bundles in the posterior anulus. The damage was characterized by the formation of a pocket filled

with nuclear material, which has also been termed a cyst by Yasuma *et al.*⁴ In the remaining 8 specimens, nuclear material was found between the outermost external layer and the posterior longitudinal ligament. The lamellae structure in these 8 cases was disrupted (Figure 6).

Discussion

Measurement and observations made in this study strengthen the hypothesis that disc herniation is the result of a cumulative process and can be due to highly repetitive flexion-extension motions with relatively low magnitudes of compressive forces. We were surprised by our observations of the herniation process in that separation between lamellae was not observed nor any rupture of anulus fibers. We propose the following explanation of the herniation mechanism from the qualitative and quantitative measures obtained from the several techniques employed in this study.

The repetitive flexion-extension motions combined with a moderate compressive load produce both an increased hydraulic pressure in the inner wall of the posterior anulus together with weakening stresses between the fibers of the inner layer. These conspire to first generate a small radial cleft from the spreading of the collagen bundles at the location of a stress concentration or the weakest area of the innermost layer. Nuclear material was advanced through the small cleft by the motion of the FSU and the intrusion of the nucleus pulposus, and the separated layer fills with nuclear material creating a pocket between the collagen fibers within the first layer. The pocket is slowly filled with additional nuclear material as the delamination proceeds. Once the pressure from the accumulated nuclear material within the la-

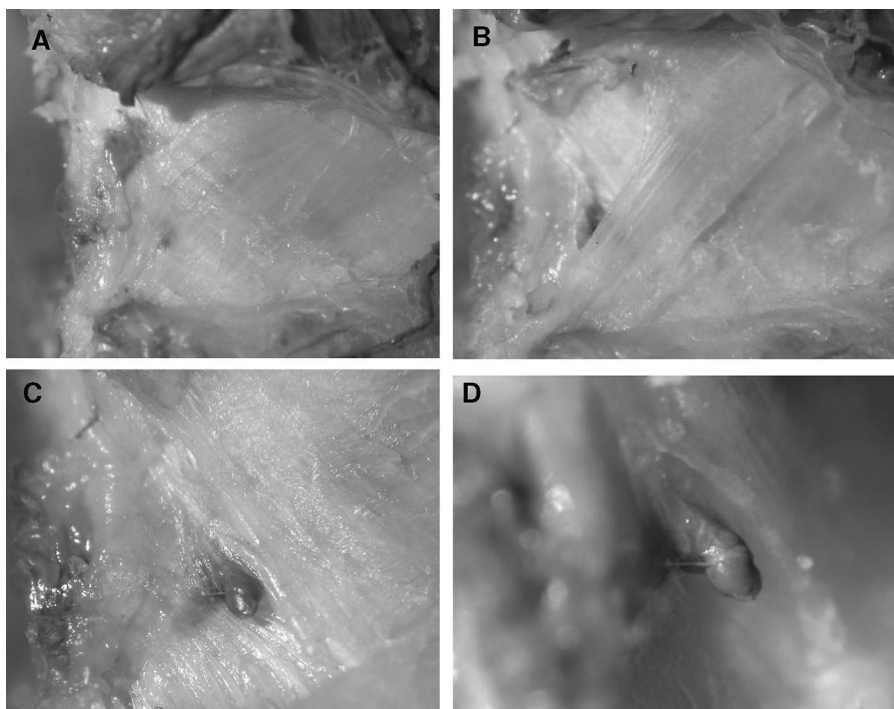
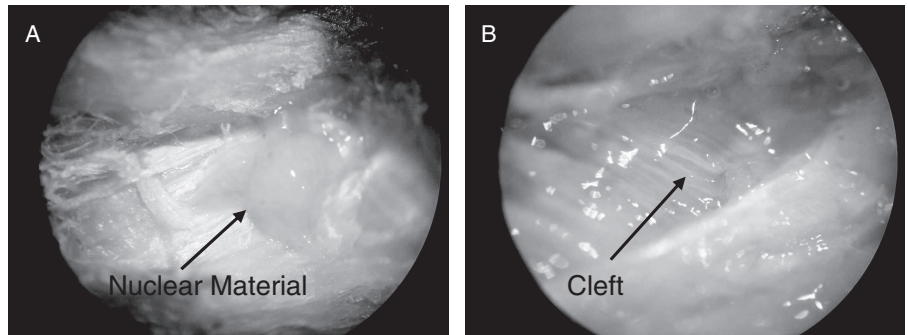


Figure 4. A dissection of the layers through the posterior anulus revealed the process of herniation. First the cleft is covered by a couple of lamellae (A). As the lamellae were removed layer by layer, the stained nucleus material becomes visible (B), removing another layer reveals the cleft through which nucleus material travels (C). The same cleft and nucleus material in a lateral view (D).

Figure 5. Dissection of the posterior annulus shows a partial herniation. Systematically dissecting the lamellae uncovered a pocket filled with stained nuclear material (A). Removing the pocket revealed a cleft in the fibers in a more inner layer through which the nucleus material had traveled (B).



mella and the FSU motion exceeds the strength of the next layer, a new cleft is produced at the weakest part. If the loading conditions are maintained, the nucleus then is forced through the new cleft into the second layer and creates a new pocket. This describes the first stage of damage and disc herniation production at a microscopic level. This cumulative type of mechanism was repeated until the nuclear material eventually reached the posterior longitudinal ligament. At this point, a complete herniation with extrusion of nuclear material was produced. Additional pockets appeared to form in the inner layers once the leading edge of nuclear material had advanced several layers heading toward the periphery of the disc. Whether these pockets were discrete from the original could not be ascertained given the extensive damage the annulus had sustained in this group of specimens. It is important to emphasize that none of the clefts was observed to form through the annulus in a straight path made by the nucleus pulposus. Perhaps this mechanism can account for the discordance of herniation detection *via* various methods. In this study, the determination of herniation from discography images agreed in 57% of the cases with the microscopic dissection (gold standard). Interestingly, a second injection of radio-opaque mixture failed to improve the visibility of exact clefts/pathways where the nuclear material passed through the posterior annulus. It is likely that the mixture was unable to pass along the 3-dimensional path made from the previous passage of nucleus pulposus without the flexion-extension motion and compressive load on the disc. This

infers that a combination of motion, load, and pressure are required to propagate nuclear material through the annulus, and not just an increase in nuclear pressure alone. Since the second injection did not increase the sensitivity of the discography, this suggests that discography in the clinical sense may be useful for detecting painful discs, but not for detecting herniated discs.

In all 12 damaged discs, nucleus pulposus filled pockets were found within lamellae of the posterior annulus and no nuclear material was found between the lamellae. The relatively more vertical inclination angle of the inner lamellar layers is postulated to be the most resistant to penetration by the nucleus pulposus. As the layers become more horizontal, and subsequently more external, the layers are likely more easily parted, and so less capable of containing the nucleus pulposus. The shape of the delamination took the same inclination angle of the layer. Two adjacent delaminations, filled with nucleus, had the same criss-cross pattern as the lamellae bundles. The within-layer spreading was only observed after the nucleus had passed through the layer. In the partially herniated specimens, no delamination was observed in the layers external to those infiltrated by nuclear material. Therefore, the delamination appeared to be due to both hydraulic stresses from nuclear liquids as well as from the applied motions and loads.

Some limitations that define the context of this work include the limited number of specimens that were used in this study. It was difficult to determine the optimal cycles of bending between initiation and complete stages of herniation. Once the herniation begins, it appears to progress relatively rapidly to the outermost layers of the annulus. However, very thorough dissection techniques were performed on all of the specimens and a consistent pattern of injury as a result of the cumulative loads applied were observed. All of the specimens used were from young and healthy porcine donors, and so all intervertebral discs exhibited hydraulic capabilities. The same mechanism of injury may not exist for discs that are degenerated. Although several studies in the literature have demonstrated the appropriateness of using porcine cervical spine segments as a model for human lumbar spine segments, anatomically, geometrically, and biomechanically,^{12,13} differences between the species may occur.

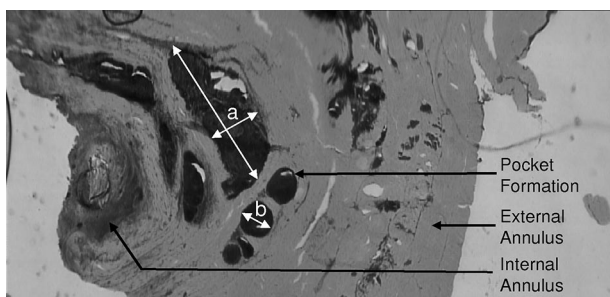


Figure 6. An image of the posterior annulus cut sagittally (stained with hematoxylin and eosin, original magnification $\times 4$) shows pocket formations filled with nuclear material (dark stain). Here pocket (A) measures 0.94 mm \times 0.34 mm and (B) measures 0.22 mm.

The histologic compositions of herniated disc fragments have been investigated in many publications.^{3–5,14} It may be that the progression of nuclear material tracking through the annulus is different depending on the age of the subjects. Hard disc herniation occurs in older patients where fibrosis is present and pieces of cartilage of the endplate and new formation of small vessels are exhibited. It has been suggested that soft disc herniation is where the primary extruded material found is nucleus pulposus.¹⁵ This observation may be due to partial herniation which lay dormant in people and then the progression continues at a later stage in life should repeated bending become excessive and sufficient.

■ Conclusion

Progressive disc herniation appears to involve a delamination process within lamellae rather than between them. This progresses under repeated bending, which initiates clefts and pockets filled with nuclear material within lamellae. We were unable to document any evidence of delamination between layers or lamellae, nor any rupture of fibers of the annulus. Interestingly, injection and detection of radio contrast mimicking *in vivo* discograms more often failed to detect or improve detection of the substantial progressive herniation documented using microscopic dissection. This research has furthered the knowledge and understanding of the mechanism of herniation. This may assist in developing prevention and treatment approaches.

■ Key Points

- The delamination process of the annulus during progressive disc herniation occurred within the lamellae rather than between them.

- No rupture or failure of any annulus fibers were detected; only clefts as adjacent fibers were separated.
- Only 4 of 8 complete herniations were identifiable by radiologic contrast discogram.

References

1. Adams MA, Hutton WC. Gradual disc prolapse. *Spine* 1985;10:524–31.
2. Gordon SJ, Yang KH, Mayer PJ, et al. Mechanism of disc rupture: a preliminary report. *Spine* 1991;16:450–6.
3. Moore RJ, Vernon-Roberts B, Fraser RD, et al. The origin and fate of herniated lumbar intervertebral disc tissue. *Spine* 1996;21:2149–55.
4. Yasuma T, Makino E, Saito S, et al. Histological development of intervertebral disc herniation. *J Bone Joint Surg Am* 1986;68:1066–72.
5. Lipson SJ. Metaplastic proliferative fibrocartilage as an alternative concept to herniated intervertebral disc. *Spine* 1988;13:1055–60.
6. Callaghan JP, McGill SM. Intervertebral disc herniation: studies on a porcine model exposed to highly repetitive flexion/extension motion with compressive force. *Clin Biomech* 2001;16:28–37.
7. Galante JO. Tensile properties of the human lumbar annulus fibrosus. *Acta Orthop Scand Suppl* 1997;100:5–91.
8. Callaghan JP, McGill SM. Frozen storage increases the ultimate compressive load of porcine vertebrae. *J Orthop Res* 1995;13:809–12.
9. Aultman CD, Drake JDM, Callaghan JP, et al. The effect of static torsion on the compressive strength of the spine: an in vitro analysis using a porcine spine model. *Spine* 2004;29:E304–9.
10. Gunning JL, Callaghan JP, McGill SM. Spinal posture and prior loading history modulate compressive strength and type of failure in the spine: a biomechanical study using a porcine cervical spine model. *Clin Biomech* 2001;16:471–80.
11. Parkinson RJ, Durkin JL, Callaghan JP. Estimating the compressive strength of the porcine cervical spine: an examination of the utility of DXA. *Spine* 2005;30:492–8.
12. Oxland TR, Panjabi MM, Southern EP, et al. An anatomic basis for spinal instability: a porcine trauma model. *Spine* 1991;14:1111–5.
13. Yingling VR, Callaghan JP, McGill SM. The porcine cervical spine as a model of the human lumbar spine: an anatomical, geometric, and functional comparison. *J Spinal Disord* 1999;12:415–23.
14. Mixer WJ, Barr JS. Rupture of the intervertebral disc with involvement of the spinal canal. *N Engl Surg Soc* 1934;2:210–5.
15. Willburger RE, Ehiosun UK, Kuhnen C, et al. Clinical symptoms in lumbar disc herniation and their correlation to the histological composition of the extruded disc material. *Spine* 2004;29:1655–61.